

Cystic Hygroma: A Rare Case Report

Dr. Shashikant Kulkarni¹, Dr. Mrinalini²

¹(Professor and Head of the Department),

²(Post graduate student)

D.Y PATIL HOSPITAL AND RESEARCH INSTITUTE, KOLHAPUR

I. Introduction

Cystic Hygroma(CH) is also known as Cystic Lymphangioma. A lymphangioma is proliferation of thin walled lymphatic vascular tissues that may or may not be filled with lymph fluid. Its incidence is estimated to be 1 case per 6,000-16,000 live births. Exact etiology is not known but alcohol has been associated with the development of lymphangiomas. No hereditary predisposition exists. Over 50% of CH present at birth and more than 90% of these congenital malformations are found in children < 2 years with males and females equally affected. CH was 1st described in the European literature by Redenbacher in 1828. We report a case of cystic hygroma, suspected on USG and confirmed with Clinical and Histopathology Report.

II. Case Report

A 19 yr old primigravida, Hindu by religion, 33 wks 4 days presented with pain in lower abdomen acute in onset, scanty mucoid blood stained discharge per vagina with decreased perception of fetal movements. It was her 1st visit to our hospital and was not undergoing regular antenatal check-ups. Her past, medical or family history were unremarkable.

On examination, vitals were stable with no abnormality in her general and systemic examination. On per abdomen examination uterus was term size, cephalic presentation, Fetal heart rate ranging from 100 – 110 bpm, head fixed with mild contractions. On per vaginal examination, cervical os admitted 2 fingers, minimal effacement, station at -1.

Report of USG showed fetal hydrocephalus with large cystic mass in posterior fossa extending upto cervical region. Her routine blood and urine investigations were normal.

She spontaneously went into preterm labor and gradually progressed to full dilatation and full effacement of cervix, station of head being +2.

A female baby, still birth of 2.3 kgs was delivered. Baby showed no signs of life, APGAR score being 0. Baby had a large cystic swelling on the occipitocervical region approx 8x8 cms with tracheal deviation and translucency was present. Post delivery mother was treated conservatively with antibiotics, analgesics and other supportive treatment.

Micro Description showed large, irregular vascular spaces lined by flattened, bland epithelial cells with fibroblastic or collagenous stroma. Stroma contained lymphocytes.

III. Discussion

Cystic hygroma (CH) or hygroma colli is characterized by abnormal accumulation of fluid in the region of the fetal neck and is one of the major anomalies associated with aneuploidy.

Prenatal diagnosis of CH via ultrasound is based on demonstration of a bilateral, mostly symmetric, cystic structure in the occipitocervical region with the lesion either septate or non septate or as a large obstructing airway mass. If such a mass is visible on ultrasonography, MRI should be performed to further delineate the mass. Chromosomal analysis either with chorionic villus sampling (CVS) or amniocentesis is accepted as the sequential step in its management. Elevated alpha fetoprotein levels in amniocentesis fluid has been reported in pregnancies with CH.

Karyotypic abnormalities are present in 25-70% of children with CH. It has been noted to be more common with Turner syndrome, Down syndrome, Klinefelter syndrome and trisomy 18 and 13, although these are not considered a cause. Also several nonchromosomal disorders like Noonan syndrome, Fryns syndrome, multiple pterygium syndrome and Achondroplasia are associated with an increased incidence of CH.

Lymphangiomas are thought to arise from a combination of the following:

- failure of lymphatics to connect to venous system
- abnormal budding of lymphatic tissue
- Sequestered lymphatic rests that retain their embryonic growth potential.

These lymphatic rests can penetrate adjacent structures or dissect along fascial planes and eventually become canalized. These spaces retain their secretions and develop cystic components because of the lack of a venous outflow tract. The nature of the surrounding tissue determines whether the lymphangioma is capillary, cavernous, or cystic. CHs tend to form in loose areolar tissue, whereas capillary and cavernous forms of lymphangiomas tend to form in muscle.

Studies using cell proliferation markers - lymphangioma enlargement is related more to engorgement than to actual cell proliferation.

Molecular studies - vascular endothelial growth factor C (VEGF-C) and its receptors may play an important role in the development of lymphatic malformations .

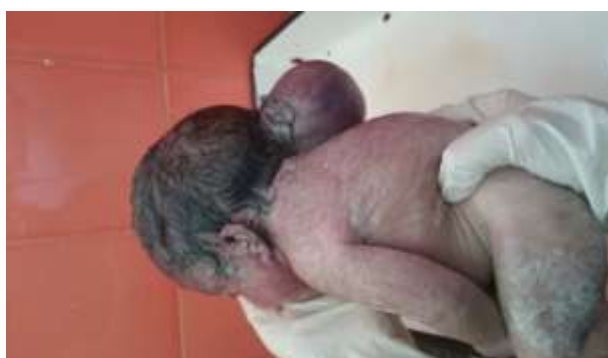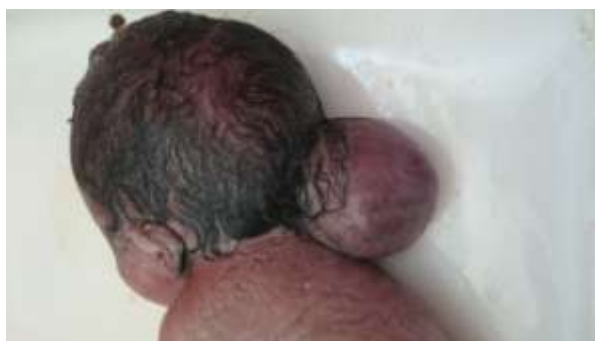Laboratory Studies - fluorescent in situ hybridization (FISH) can be used to evaluate for CH in prenatal chromosomal analysis(Chromosomes 13, 18, 21, X and Y are specifically mentioned).

Ultrasonography - least invasive study.It can be used to detect CH in utero - Echographic visualization of multiple septae in fetal CH has been postulated to be a poor prognostic indicator.

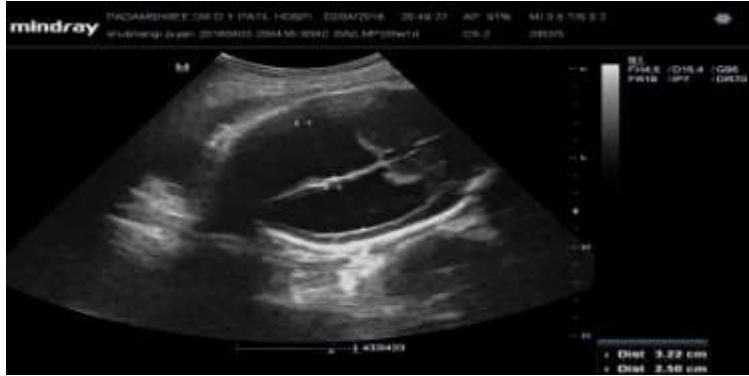
MRI - provides the best soft tissue detail and can delineate the relationship of the lesion to underlying structures.CHs appear hyperintense on T2-weighted images and hypointense on T1-weighted images.

IV. Conclusion

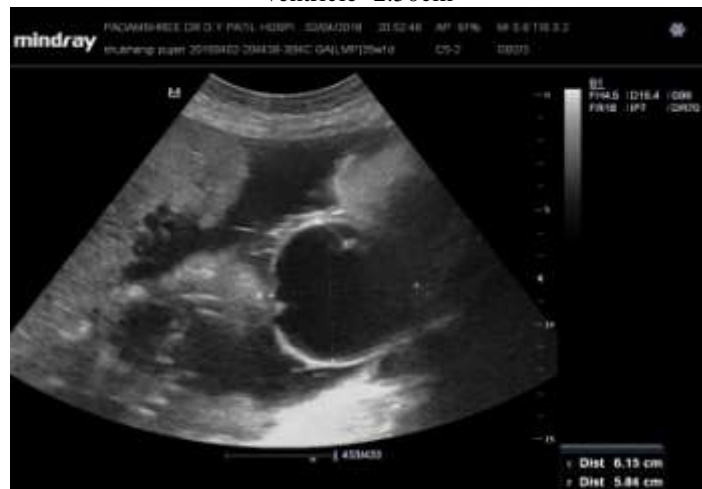We want to emphasize that the outcome of a pregnancy complicated by fetal CH is poor but couples can be encouraged to complete the pregnancy with some future risks regarding neurologic development of the infant, especially when the fetus is euploid and structurally normal. Further studies are needed to accurately distinguish between outcomes for fetuses and to provide more substantial information to the couples, for the classification of CH and for the management of pregnancies in which the fetus has this lesion.



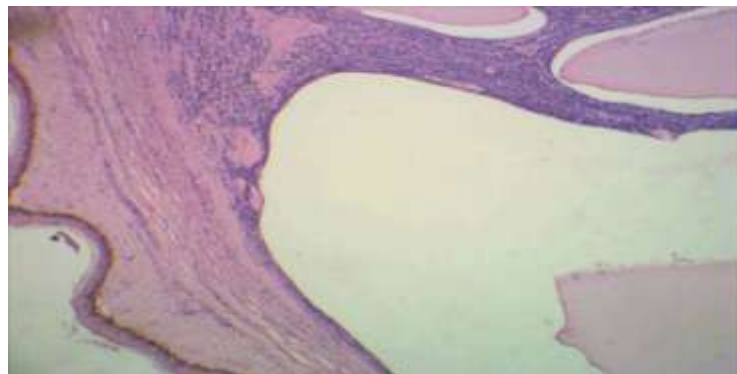
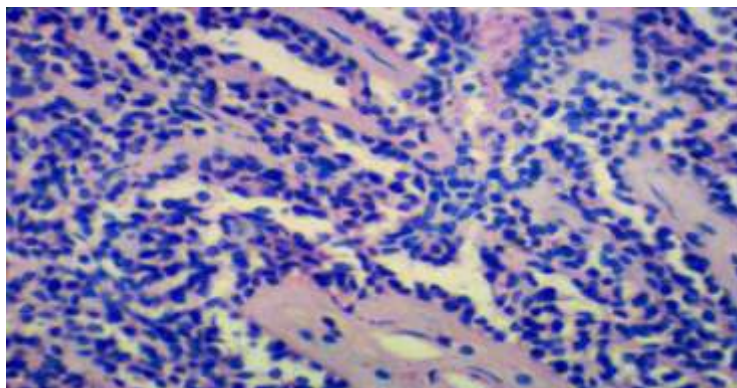
Gross finding of the cystic mass seen on the posterior aspect of neck of the still born.

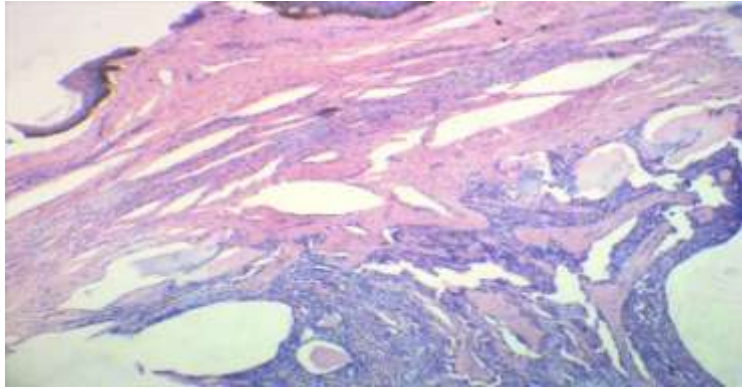


Transverse diameter of body of left lateral ventricle- 3.22cm Transverse diameter of body of right lateral ventricle- 2.50cm



A large cystic lesion -6.1x5.8 cm noted in the region of cerebellum and upper cervical spine





Micro description: large irregular vascular spaces lined by flattened, bland epithelial cells with fibroblastic stroma. Stroma contains lymphocytes.

References

- [1] Shaffer LG, Rosenfeld JA, Dabell MP, Coppinger J, Bandholz AM, Ellison JW, et al. Detection rates of clinically significant genomic alterations by microarray analysis for specific anomalies detected by ultrasound. *Prenat Diagn* 2012; 32: 986-995, doi: 10.1002/pd.3943.
- [2] Wapner RJ, Martin CL, Levy B, Ballif BC, Eng CM, Zachary JM, et al. Chromosomal microarray versus karyotyping for prenatal diagnosis. *N Engl J Med* 2012; 367: 2175-2184, doi: 10.1056/NEJMoa1203382.
- [3] Committee Opinion No. 581: the use of chromosomal microarray analysis in prenatal diagnosis. *Obstet Gynecol* 2013; 122: 1374-1377, doi: 10.1097/01.AOG.0000438962.16108.d1.4) C.Y. Sanhal et al, Prenatal management, pregnancy and pediatric outcomes in fetuses with septated cystic hygroma. *Brazilian Journal of Medical and Biological Research* (2014) 47(9): 799-8035) Shetty, Aditya, D'Souza, Donna. "Lymphangioma". *Radiopaedia*. UBM Medica network. Retrieved 22 nov 2014